

Collagen remodeling induced by non-ablative treatment with the Polaris WR™ using the combination of diode laser and bi-polar RF energies

by

Gregory S. Keller,

MD, Associate Clinical Professor, Facial Plastic Surgery, UCLA Medical Center

Jesse E. Smith,

MD, Clinical Instructor, Facial Plastic Surgery, UCLA Medical Center

ABSTRACT

Objective - The purpose of this study was to assess the clinical improvements achieved from using the Polaris WR™ system for facial and neck ageing signs resulting from collagen remodeling. This study was focused on evaluating the improvement of nasolobial folds, redundant folds of lower eyelids, loose skin of the cheeks, neck and other deep wrinkles, as well as improvement in skin texture and laxity.

Methods - A total of 31 patients (29 females and 2 males) between the ages of 26 and 72 years (average age 50 years), with Fitzpatrick skin types I to IV, were included in this prospective study. All patients had the presence of collagen ageing signs. Three areas were treated on each patient. All patients received a total of 4 treatments three weeks apart with a follow-up visit 3 weeks after their last treatment. The most common treatment indications were both an improvement in the appearance of wrinkles and skin texture.

Results - All patients showed at least some improvement in the appearance of wrinkles, eyebrow positioning, skin texture and laxity. Most patients were satisfied with the success of treatments. Patients considered the treatment to be relatively painless, except near the hairline and the upper lip.

Conclusions - Treatment with the Polaris WR results in significant quantitative improvements in facial and neck wrinkles, skin tightening, skin texture and laxity. Continued incremental improvements were noted at 3 weeks follow-up, indicating ongoing dermal collagen remodeling after the treatment. Under careful clinical observation, dramatic improvements were observed in patient satisfaction of facial and neck skin tightening, as well as improvements in skin texture and laxity.

INTRODUCTION

It is known that collagen varies genetically and structurally. Collagen breakdown increases with chronological age and photoageing¹. Sun damage, free radicals, age-related hormonal changes, and smoking are all factors that contribute to this breakdown. While fibroblasts normally replace damaged collagen fibers with new ones, the ability of fibroblasts to replace collagen is compromised by natural ageing and environmental stress. Although collagen fibres form a loose interlacing network that is deformable², increased collagen breakdown leads to thinning and loss of the elastic fiber network in the dermis. This breakdown results in the formation of wrinkles, especially in sun-exposed areas of the skin which are most prone to wrinkles and imperfections.

By using a combination of two types of energies - optical and conductive RF, thermal collagen remodeling represents an innovative approach in cosmetic medicine.

The Polaris WR delivers a precise yet non-invasive combination of optical and RF energies through the skin's surface. As both ranges of energy supplement each other, the limitations of single energy technologies can be overcome by using this innovative system.

The purpose of this study was to assess the clinical improvements achieved from using the Polaris WR system for facial and neck ageing signs resulting from collagen remodeling. This study was focused on evaluating the improvement of nasolobial folds, redundant folds of lower eyelids, loose skin of the cheeks, neck and the other deep wrinkles as well as improvement in skin texture and laxity. As a result of the laser-RF-tissue interaction, it was anticipated that collagen remodeling would result in clinical benefits.

The amount of observed skin tightening is largely dependant on factors such as the energies used, tissue thickness and anatomic

location³. Eyelid tissue is generally thinner when compared to other facial skin (Figure 1, Zone 4), and loose, folded eyelid tissue tightens very readily and often profoundly. Tightening of cheek skin (Figure 1, Zone 2) is important in reducing nasolabial fold prominence and “jowls” under the jaw line. Besides the level of energy applied, the amount of tightening observed in this area depends on the amount of treatment passes performed over the facial and neck areas. It may be necessary to make more treatment passes in order to reach the optimal endpoints of erythema and swelling (edema) of the skin. By targeting high points of glabellar and forehead lines (Figure 1, Zones 1-2), better smoothing of these areas may be achieved.

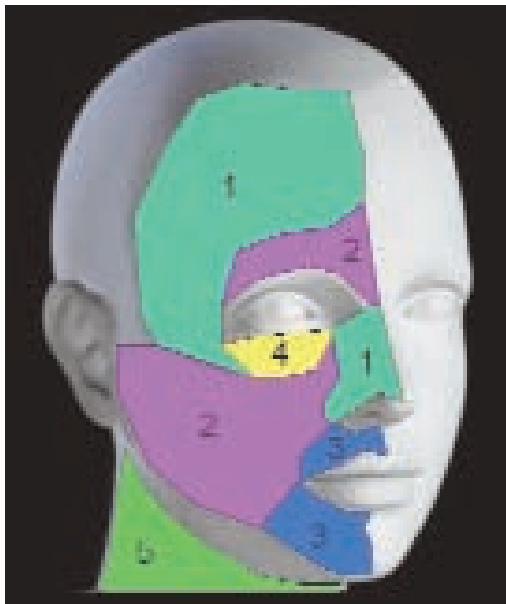


Figure 1

METHODS

A total of 31 patients (29 females and 2 males) between the ages of 26 and 72 years (average age, 50 years), with Fitzpatrick skin types I to IV (Table 1), were included in this prospective study. All patients had the presence of collagen ageing signs. Three areas were treated on each patient (Table 2). Patients were excluded from the study if they were pregnant, had undergone other facial laser treatments, had received collagen or botulinum toxin injections, or had taken Accutane within the past 6 months. All patients received a total of 4 treatments 3 weeks apart with a follow-up visit scheduled 3 weeks after their last treatment in order to document study results. The most common treatment indications were

improvement in the appearance of wrinkles and improvement in skin texture (Table 3).

The Polaris WR™ (Syneron Medical Inc., Yokneam, Israel) was used for treatments in the study. Polaris WR uses both a diode laser at 900 nanometers and bipolar conducted radiofrequency. The superficial epidermis was protected from thermal over-load by the contact cooling on the applicator tip. Prior to initiating treatment, the surface of the skin was hydrated using a thick layer of water-based transparent gel (2-3mm). Starting optical energies of 15-16 J/cm² and RF of 80 J/cm³ were applied when treating the soft areas (cheeks, lips, nasolabial folds and neck- Figure 1, Zones 2,3 and 5). The same energies were applied to over-bone areas (forehead, zygomatic area - Figure 1, Zones 2, 4). Once the optimal endpoints were observed, treatment was completed using the same energy levels. The number of treatment passes performed during each session depended on what was needed to achieve the optimal endpoints. Typically, the number of treatment passes needed to see the desired endpoints varies from 3 to 4. Full face treatments were performed by using a non-repetitive pulse mode. If no adverse effects occurred with initial treatment settings, the laser and RF fluencies were increased by 10 - 15% for subsequent treatments. Patients were instructed to protect the treated area with a sunblock containing SPF 30 or higher to help prevent the occurrence of hyper-pigmentation from post-treatment sun exposure.

Table 1.

| Skin Type | Number of patients |
|-----------|--------------------|
| I | 2 |
| II | 15 |
| III | 8 |
| IV | 7 |

Table 2.

| Area treated | Number of patients |
|--------------|--------------------|
| Forehead | 25 |
| Peri-orbital | 17 |
| Peri-oral | 8 |
| Cheeks | 12 |
| Neck | 18 |

Table 3.

| Treatment indication | Number of patients |
|--------------------------|--------------------|
| Wrinkles | 30 |
| Skin texture improvement | 14 |

Collagen remodeling induced by non-ablative treatment with the Polaris WR™ using the combination of diode laser and bi-polar RF energies

by
Gregory S. Keller,

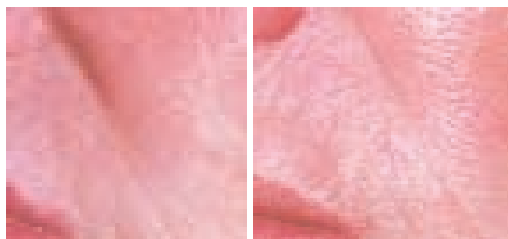MD, Associate Clinical Professor, Facial Plastic Surgery, UCLA Medical Center

Jesse E. Smith,
MD, Clinical Instructor, Facial Plastic Surgery, UCLA Medical Center

RESULTS

All patients showed at least some improvement in the appearance of wrinkles, eyebrow positioning, skin texture and laxity. With respect to the level of improvement achieved, most patients were satisfied with the success of treatments. While all patients saw results, a number of patients expected to see more. Only 1 patient was not satisfied with the outcome. During the treatments, most patients experienced slight discomfort, but were unanimous in stating that the laser treatment was much more pleasant with cooling than without. One patient reported moderate pain. In summary, patients considered the treatment to be relatively painless except near the hairline and the upper lip.

Seven patients reported mild post-treatment redness (most frequently peri-oral) and swelling in the treated areas that lasted for 24 hours. A small number of patients experienced itching that also lasted for 24 hours and was helped with antihistamines. Superficial scabs were observed on 2 patients and lasted for 3-5 days. No other complications or adverse effects were observed after treatment.



Before

After

CONCLUSION

Treatment with the Polaris WR results in significant quantitative improvements in facial and neck wrinkles, skin tightening, skin texture and laxity. Continued incremental improvements were noted at 3 weeks follow-up, indicating ongoing dermal collagen remodeling after the treatment. Higher energies should be used to treat softer areas (cheeks, neck). Conversely, lower energies can be used to treat more sensitive areas over bone areas (forehead, zygoma).

Under careful clinical observation, dramatic improvements were observed in patient satisfaction of facial and neck skin tightening as well as improvement in skin texture and laxity.

REFERENCES:

1. Voorhees JJ et al. *J Invest Dermatology* 2000; 114: 480.
2. Goldman MP, Fitzpatrick RE. *Cutaneous Laser Surgery: The Art and Science of Selective Photothermolysis*, 1999: Mosby.
3. Horn TD, Mascaró JM, Mancini AJ, Salasche SJ, Saurat JH, Stingl G. *Dermatology*, 2003: Mosby.

COMMENTARY

The current demand and desire for non-invasive and non-ablative technology to address the cosmetic problem of loose, lax skin (traditionally being the realm of cosmetic surgery) have seen the development of **light** and **radiofrequency** based modalities.

This small study manages to show us that **combined light and RF energy** used in a non-ablative fashion could achieve some skin tightening of facial and neck skin.

However, it also raises more questions regarding this technology that the author did not address. These include:

- What advantage is there in combining RF and photon modalities, when it has been shown that these individual modalities can each achieve such results?
- Is there a synergistic effect that gives better and more reliable results?
- If the RF works with 900nm wavelength (as in Polaris) then would other infrared wavelengths be just as effective?

Perhaps a study comparing the results of **individual RF, individual light therapy** and **combined RF/Light treatments** would more be valuable in determining the answers to these questions.

Another question is whether any particular areas of the face or neck are more responsive to this treatment (for example, the eye area or the neck). It would also be helpful to know the optimal treatment parameters.

Further, this study had a short follow up period and did not speculate as to how long the improvements could be expected to last - weeks, months or years?

In my opinion more detailed studies will be needed to answer these questions in order to allow us to offer sound recommendations to our patients.

Dr Peter Muzikants